

# Choosing anatomical-prior strength for MAP SPECT reconstruction to maximize lesion detectability

Andre Lehovich, *Member, IEEE*, Howard C. Gifford, *Member, IEEE*, Peter B. Schneider, and Michael A. King, *Senior Member, IEEE*

**Abstract**—With the widespread availability of SPECT/CT systems it has become feasible to incorporate prior knowledge about anatomical boundaries into the SPECT reconstruction process, thus improving observer performance on tasks of clinical interest. We determine the optimal anatomical-prior strength for lesion search by measuring area under the LROC curve using human observers. We conclude that prior strength should be chosen assuming that only organ boundaries are available, even if lesion boundaries will also be known some of the time. We also test whether or not the presence of anatomical priors affects the observer's strategy, and conclude that mixing images with and without priors does not hurt reader performance when priors are not available. Finally, we examine whether using an anatomical prior in SPECT reconstruction helps observer performance when the observer already knows the possible lesion location, and conclude for this task anatomical priors do not provide the same improvement seen in search tasks.

## I. INTRODUCTION

OUR goal is to leverage the high-resolution anatomical information provided by the CT portion of a SPECT/CT scan to improve the quality of the SPECT images. We do this by incorporating knowledge about the anatomy into the SPECT reconstruction process. (The same approach should also work with SPECT/MRI, if such scanners appear on the market.)

Last year at MIC we presented data showing that incorporating prior knowledge about patient anatomy into maximum-a-posteriori (MAP) SPECT reconstruction improves image quality, as measured by human performance on a lesion-search task [1]. The prior strengths  $\beta$  used in [1] were chosen using a model observer; unfortunately the model predictions did not correlate well with the human observer's scores. This paper investigates human performance over a broad range of prior strengths to find the optimal value.

We also consider two related questions: Incorporating prior knowledge about the lesion boundaries greatly improves performance; if this prior is available only some of the time, does that change the observer's strategy and hurt performance in cases where the prior isn't available? Our previous studies found anatomical priors help humans performing a search task;

Manuscript received November 16, 2007. This work was supported by the U.S. National Institute of Biomedical Imaging and BioEngineering under grant R01 EB002798. The contents are solely the responsibility of the authors and do not necessarily represent the official views of the National Institutes of Health.

The authors are with the University of Massachusetts Medical School, Worcester, MA 01655 USA (e-mail: Andre.Lehovich@umassmed.edu).

does an anatomical prior still help even if the observer already knows where to look for the lesion?

## II. METHODS

### A. Reconstruction priors

We simulated  $^{67}\text{Ga}$ -citrate SPECT scans using the MCAT phantom [2] and 1-cm spherical lesions as input to the SIMIND Monte Carlo simulator [3]. Simulated data was then reconstructed using the Rescaled Block Iterative (RBI) algorithm [4] with no prior, and with De Pierro's maximum-a-posteriori (MAP) algorithm [5] using three different forms of prior knowledge about the anatomy. Full details on computing the priors are given in [6]. Prior strength is determined by a parameter  $\beta$ , with  $\beta = 0.0$  corresponding to no prior, and  $\beta = \infty$  ignoring the data in favor of the prior. We iterated all MAP algorithms to convergence. RBI used settings optimized in previous model- and human-observer studies [7].

The first prior used knowledge of the organ boundaries (but not lesion boundaries) to define regions of quadratic smoothing. Such a scenario might arise during a SPECT/CT scan in which a hot lesion is apparent in the nuclear images but not in CT, while organs such as the liver can be seen with both modalities.

The second prior had knowledge of both the organ boundaries, as well as lesion boundaries. This corresponds to a situation in which the lesion can be seen using both SPECT and CT.

The third prior had knowledge of the organ and lesion boundaries, but also had pseudo-lesion boundaries when a lesion was not actually present. This corresponds to a situation in which a lesion-like structure can be seen in CT, but does not have increased radiotracer uptake, as might be the case for necrotic tissue or a successfully treated tumor.

### B. Human observer studies

Three different human observer studies were conducted using the reconstructions. We broke the studies into sets of 50 training images, for which the observer received feedback about the truth after each image, and 100 testing images with no feedback. Half of the images in each set were lesion present, the other half absent. We then pooled two sets (total of 200 testing images) to compute a figure of merit for each reader/prior pair.

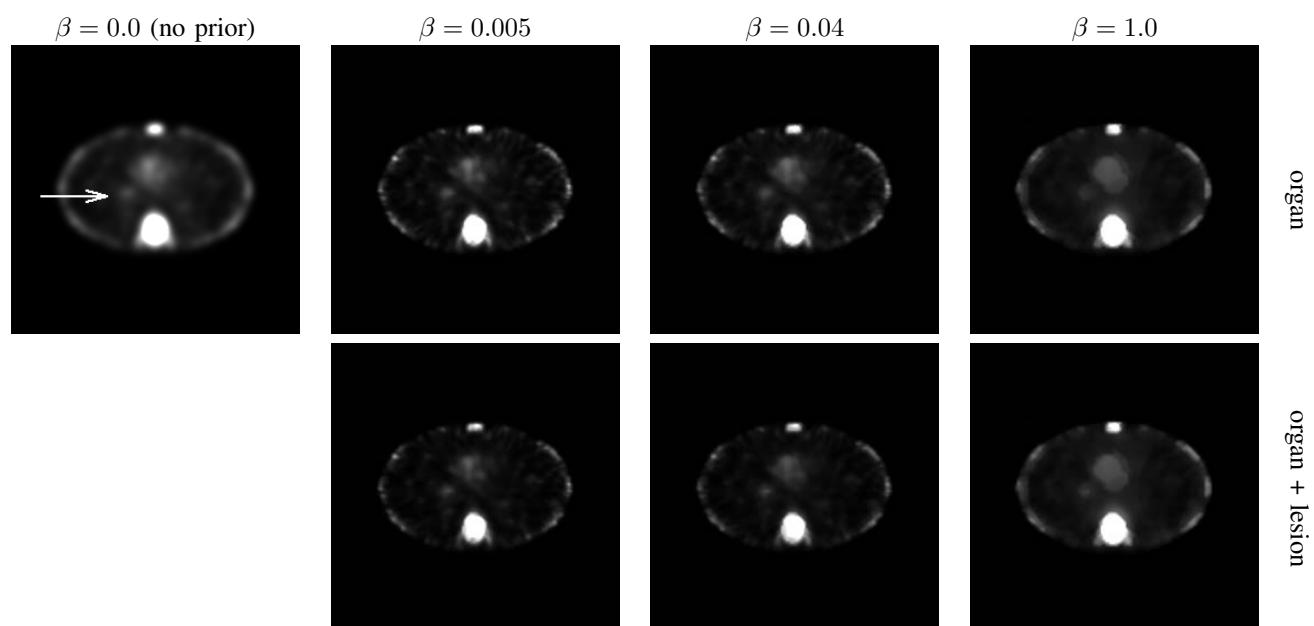


Fig. 1. Sample data set reconstructed using several priors. Prior strength is given by  $\beta$ . The arrow indicates location of a lesion.

1) *Determining optimal value of  $\beta$* : In the first study we examined observer performance as a function of prior strength  $\beta$  for all three priors. Sample reconstructions are shown in Fig 1. Earlier studies using a model observer suggested the optimal value was in the vicinity of  $\beta = 0.04$  [6]. To confirm this we checked a variety of prior strengths,  $\beta \in \{0.02, 0.04, 0.06, 0.1, 0.2, 1.0\}$ , with a mixture of lesion contrasts. For each image the observer selected the most likely lesion location, and indicated his confidence that it was a lesion. We used area under the LROC curve [8] as the figure of merit. This study was read by three scientists in our medical-physics research group.

2) *Mixing different priors together*: In the second study we checked to see if having prior knowledge about the lesion boundary for only some patients, as would be the case in clinical practice, hurts observer performance on cases where the lesion boundary isn't available. For this study we used only  $\beta = 0.04$  and considered only two priors: organ boundary, and both organ and lesion boundaries. We prepared sets in which images reconstructed using both priors were randomly interleaved. After reading, we extracted out each strategy, analyzed it separately, and compared performance with a control in which the observers only read one strategy at a time. We used area under the LROC curve as the figure of merit. This study was read by three scientists in our medical-physics research group.

3) *Known lesion location*: In the first two studies the observer had to search the image for a lesion. In the third study we gave the observer a cue about the lesion's possible location, to test if anatomical priors improve observer performance even when the lesion's location is already known. This is a location-known-exactly (LKE) signal-detection task. We tested all three priors with  $\beta = 0.04$ . As a control we used images reconstructed by the RBI algorithm without any anatomical prior. Cuing the observer to possible lesion location makes

the task much easier, so we had to lower the lesion contrast for this study. We used area under the ROC curve as the figure of merit. This study was read by three scientists in our medical-physics research group, and by one nuclear-medicine physician from our clinic.

### III. RESULTS

#### A. Determining optimal value of $\beta$

Fig. 2 shows human observer performance as a function of prior strength  $\beta$  for each of the three anatomical priors. Symbols indicate performance of each observer. The lines are a LOESS fit across all observers and prior strengths  $\beta$ . All three priors seem to have about the same amount of observer variability.

The organ-only prior shows a performance plateau from  $\beta \approx 0.02$  to  $\beta \approx 0.1$ , and then drops for higher values of  $\beta$ . (In [1] we did a study with  $\beta = 0.005$  and found that performance also drops off for lower values of  $\beta$ .)

The priors using organ+lesion and organ+pseudo-lesion boundaries show somewhat different behavior; performance reaches a break somewhere in the range  $0.1 < \beta < 1.0$ , and then gradually falls off for higher values of  $\beta$ .

#### B. Mixing different priors together

Results of mixing together images with and without an anatomical prior are shown in table I. No difference is found.

#### C. Known lesion location

Fig. 3 shows results of the LKE study. We found a large variability between readers, but no clear difference between priors. A two-way ANOVA failed to find any significant difference between the priors ( $p = .13$ ).

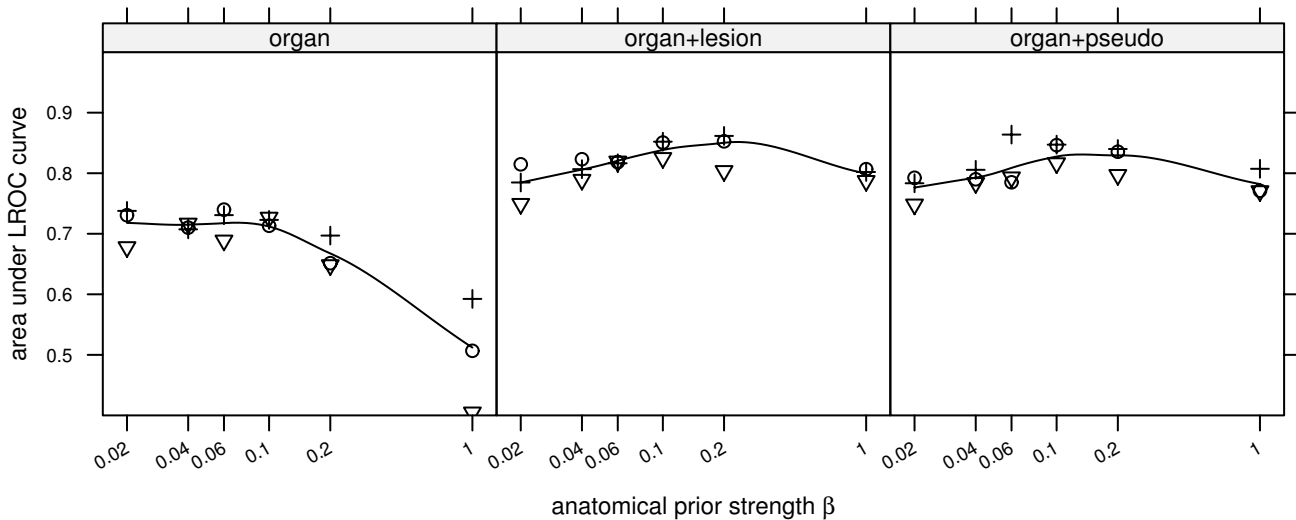


Fig. 2. Observer performance (area under LROC curve) as a function of prior strength  $\beta$  for three different types of prior anatomical knowledge.

TABLE I  
AVERAGE ROC PERFORMANCE OF 3 OBSERVERS READING IMAGES WITH DIFFERENT PRIORS.

|                                    |       |
|------------------------------------|-------|
| not mixed organ (control)          | 0.679 |
| unmixed organ                      | 0.674 |
| not mixed organ & lesion (control) | 0.777 |
| unmixed organ & lesion             | 0.781 |

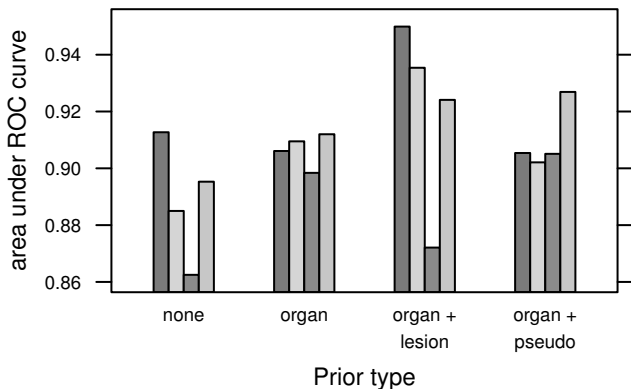


Fig. 3. Observer performance (area under LROC curve) on an LKE detection task.

#### IV. DISCUSSION

The optimal prior strength varies depending on how much knowledge about the anatomy is available. If lesion boundaries are not available, the optimal value is somewhere in the plateau of  $0.02 \leq \beta \leq 0.1$ . However if lesion boundaries are known then the peak occurs for a somewhat stronger prior, in the range  $0.1 < \beta < 1.0$ ; in this range performance without the lesion prior drops off markedly. In clinical practice we won't know whether or not lesion boundaries are included in the

prior, therefore we suggest tuning prior values assuming lesion boundaries are not available.

Although we have found that anatomical priors help observer performance on search tasks [1], especially if the lesion boundary is available, we do not find that anatomical priors help if the lesion location is already known. There are several possible explanations for this: The images used in the LKE ROC study have substantially lower lesion contrasts than those used for the LROC studies. It is possible that anatomical priors are less helpful with low-contrast lesions than at higher contrasts. (Note that all the reconstruction approaches considered here are non-linear.) A second possible explanation is that the priors help more for search tasks than for LKE detection tasks, regardless of lesion contrast. A third possible explanation is that the improvement due to priors is small enough that it can only be detected using the improved statistical power of LROC over ROC [8].

So far our work has concentrated on the quadratic prior fully described in [6]. Several other papers presented at MIC this year introduced promising new anatomical priors; it is possible that these new priors can improve observer performance.

#### V. CONCLUSIONS

We recommend being conservative in the amount of prior anatomical knowledge assumed when choosing prior strengths. In particular, one should not assume that lesion boundaries are available.

We did not find that anatomical priors improved observer performance on an LKE detection task.

We found that having priors only some of the time did not hurt performance when they were not available, suggesting that the priors do not change the observer's strategy.

## REFERENCES

- [1] A. Lehovich, P. P. Bruyant, H. C. Gifford, P. B. Schneider, S. Squires, R. Licho, G. Gindi, and M. A. King, "Human-observer LROC study of lesion detection in Ga-67 SPECT images reconstructed using MAP with anatomical priors," in *2006 IEEE Nuclear Science Symposium Conference Record*, Oct. 2006, pp. 1699–702.
- [2] B. M. W. Tsui, X. D. Zhao, G. K. Gregoriou, D. S. Lalush, E. C. Frey, R. E. Johnston, and W. H. McCartney, "Quantitative cardiac SPECT reconstruction with reduced image degradation due to patient anatomy," *IEEE Trans. Nucl. Sci.*, vol. 41, no. 6, pp. 2838–44, Dec. 1994.
- [3] M. Ljungberg and S.-E. Strand, "A Monte Carlo program for the simulation of scintillation camera characteristics," *Comput. Methods Programs Biomed.*, vol. 29, no. 4, pp. 257–72, Aug. 1989.
- [4] C. L. Byrne, "Accelerating the EMML algorithm and related iterative algorithms by rescaled block-iterative methods," *IEEE Trans. Image Process.*, vol. 7, no. 1, pp. 100–9, Jan. 1998.
- [5] A. R. De Pierro, "A modified expectation maximization algorithm for penalized likelihood estimation in emission tomography," *IEEE Trans. Med. Imag.*, vol. 14, no. 1, pp. 132–7, Mar. 1995.
- [6] P. P. Bruyant, H. C. Gifford, G. Gindi, and M. A. King, "Numerical observer study of MAP-OSEM regularization methods with anatomical priors for lesion detection in  $^{67}\text{Ga}$  images," *IEEE Trans. Nucl. Sci.*, vol. 51, no. 1, pp. 193–7, Feb. 2004.
- [7] H. C. Gifford, M. A. King, M. V. Narayanan, P. H. Pretorius, and M. S. Smyczynski, "Effect of block-iterative acceleration of Ga-67 tumor detection in thoracic SPECT," *IEEE Trans. Nucl. Sci.*, vol. 49, no. 1, pp. 50–5, Feb. 2002.
- [8] R. G. Swensson, "Unified measurement of observer performance in detecting and localizing target objects on images," *Med. Phys.*, vol. 23, no. 10, pp. 1709–25, Oct. 1996.